JOURNAL OF PURE SCIENCE AND SCIENCE EDUCATION (JOPSSED)

A PUBLICATION OF THE
SCHOOL OF SECONDARY EDUCATION (SCIENCE PROGRAMMES)
EMMANUEL ALAYANDE COLLEGE OF EDUCATION, OYO
E-mail: jopssedeacoedoyo@gmail.com

VOLUME 14, ISSUE 1, 2022

EDITORIAL BOARD

Editor-in-Chief
Dr (Mrs) O. O. Adeboye

Associate Editors
Dr S. M. Raimi
Dr (Mrs) C. B. Idowu
Dr P. I. Farayola
Dr P. A. Amao
Dr (Mrs) A. I. Adeagbo
Dr F. O. Ibikunle
Dr M. A. Amusat
Dr (Mrs) A. A. Agoro

Secretary
Mr. O. P. Ojo

Consulting Editors
Prof. J. O. Babalola
Prof. M. K. Akinsola
Dr E. O. Ogunwande
Prof. (Mrs) F. O. Akinpelu
Prof. B. O. Ogundele
Prof. (Mrs.) S. M. Afolabi

EDITORIAL COMMENT

The Journal of School of Secondary, Education (Science Programmes) (JOPSSED)a publication of original research report of Pure Science and Science Education. Publishingthis Journal has brought together great minds and dedicated academic scholars to helpreview and select quality manuscripts worthy of the objective and philosophy of the journal. The assessment of the articles had gone through peer reviewers many of them rendered their services promptly, enthusiastically and without charge, we remain ever grateful.

The journal will continue to move knowledge and research forward in a purposeful way through scholarly publishing of quality articles for education, technological and professional advancement.

The Editorial board ensures there is no delusive information in the journal and hope that the articles will deepen professional knowledge and raise the academic savviness of our readers.

Dr. Omolara Olubunmi ADEBOYE

TABLE OF CONTENTS

Titles	Authors	Pages
Histo-Morphometric Assesssment of the effect of Methanolic Extract of *Annona muricata* (Sour Sop) on Gastric Ulcer in Rats	OJO Gideon B., WOJUOLA Oluwatosin, OJO Femi T., BALOGUN Olubunmi A. & DAWODU Simon E.	1 – 13

Histo-Morphometric Assesssment of the effect of Methanolic Extract of *Annona muricata* (Sour Sop) on Gastric Ulcer in Rats

OJO, Gideon B[1, 3]; **WOJUOLA,** Oluwatosin[1]; **OJO,** Femi T[2]; **BALOGUN**, Olubunmi A[1]; **& DAWODU**, Simon E[3].

[1] **Department of Anatomy, Faculty of Basic Medical and Health Sciences, Bowen University, Iwo, Nigeria**
[2] **Department of Biology, School of Science, Federal College of Education Special, Oyo, Nigeria**
[3] **Department of Medical Biology and Genetics, Near East University, Lefkosa, Cyprus**

Abstract

The popular fruit tree of Annona muricata L. known as sour sop is a widely distributed plant in the central and south America and tropical countries. Leaves of Annona muricata has been reported to possess antioxidant and anti-inflammatory activities. The anti-ulcer study in rats [three groups, n=7] was performed with a dose of 200mg/kg of Annona muricata. In this study, the gastro-protective effects of the methanolic extract of Annona muricata leaves were investigated against ethanol-induced gastric injury models in rats. Gross and histological features showed the antiulcerogenic characterization of methanolic extract of Annona muricata. There was significant suppression on the ulcer lesion of rat pre-treated with it, which was observed by an increase in the thickness of the mucosa, attenuation of infiltration of leukocyte and attenuation of haemorrhage.

Keywords: Ulcer, Annona muricata, Sour sop, Antiulcerogenic, antioxidant, mucosa thickness

Introduction

Soursop '*Annona muricata*'

Soursop is believed to be indigenous to most of the warmest tropical regions of the world. It is a small upright evergreen tree that grows up to 6 metres tall. It has large dark and shiny green and leathery leaves which has pungent odour when crushed. The flowers are large, with yellow or greenish-yellow colour. The fruit of the tree is large and has a heart-like shape, covered with small spine-shaped structures. The pulp is fleshy, soft and white in colour, with a slightly sour-acid taste. The fruit may contain as many as 100 black seeds. In most tropical regions of the world the plant grows, it is often referred to as a "miracle tree" perhaps because of its healing effect (Morton, 1987).

Figure: 1.1.1 Soursop Fruit.

Scientific Classification of *Annona muricata*

Kingdom:	Plantae
Clade:	Angiosperms
Clade:	Magnoliids
Order:	Magnoliales
Family:	Annonaceae
Genus:	Annona
Species:	A. muricata

Binomial name: *Annona muricata* L.

Synonyms. Annona cearensis Barb. Rodr. Annona macrocarpa Wercklé Annona crassiflora Mart. Guanabanus muricatus M. Gómez Guanabanus muricatus (L.) M. Gómez

Annona bonplandiana Kunth *Annona muricata* Vell.

In natural medicine practice, all parts of the soursop tree are used as medicine, including the roots, barks, stems, leaves, fruits and the seeds of the fruit. Each part of the tree has long been shown to have different therapeutic properties. Generally, it is known that soursop has a broad spectrum antimicrobial, antispasmodic anti-diabetic, antioxidant, analgesic, anti-aging, anti-inflammatory, astringent, cardio-tonic, diuretic, emetic, liver-tonic, immunity boosting, anti-cancer, anti-ulcerogenic activities (Holdsworth *et al.,* 1990)

Peptic Ulcer.

This is a suppurating lesion of the mucous membrane lining the alimentary canal. Peptic ulcers are defects in the gastric and duodenal mucosa that extend through the muscularis mucosa. Gastric ulceration is a benign lesion on the mucosal epithelium upon exposure on the stomach to excess acid and aggressive pepsin activity. (Brzozowski *et al.,* 2000). In spite of the rapidly changing concept of gastric ulcer management from conventional vagotomy, prostaglandin anagoges, hydrogen receptor antagonists and antacids to proton pump inhibitors, gastrointestinal toxicity remains an impediment to their application in clinical practice. Specifically, gastrointestinal toxicity of nonsteroidal anti-inflammatory drugs origin may be as high as 4-8% per year and the complications are even higher for those with additional risk factors such as prior history of ulcer disease. (Drini, 2017)

In the event of acid and pepsin entering the epithelial cells, additional mechanisms are in place to reduce injury. Within the epithelial cells, ion pumps in the basolateral cell membrane help to regulate intracellular PH by removing excess hydrogen ions. Through the process of restitution, healthy cells migrate to the site if injury. Mucosal blood flow removes acid that diffuses through the injured mucosa and provide bicarbonate to the surface epithelial cells.

Under normal conditions, a physiologic balance exists between gastric acid secretion and gastroduodenal mucosal defence. Mucosal injury and thus, peptic ulcer occurs when the balance between the aggressive factors and the defensive mechanisms is disrupted. Aggressive factors such as NSAIDs, *Helicobacter pylori* infection, alcohol, bile salts, acids and pepsin, can alter the mucosal defence by allowing back diffusion of hydrogen ions and subsequent epithelial cell injury. The defence mechanism includes tight intercellular junctions, mucus, mucosal blood flow, cellular restitution, and epithelial renewal.

Justification.

Various synthetic anti-ulcer drugs are presently available and some of these like; Cimetidine, Misoprostol, Ranitidine, Omeprazole and Esomeprazole are employed to manage and cure gastric ulcer. However, each of these drugs confers simpler to severe side effects, prompting a search for non-toxic easily accessible and affordable anti-ulcer medication, Hence my research work.

Aims and Objectives.

(1) To prepare methanolic extract of *Annona muricata.*

(2) To investigate the anti-ulcerogenic activities of *Annona muricata* leaf.

(3) To evaluate some of the effects of extract of *Annona muricata* on the stomach histology.

Literature Review

It is a general belief that peptic ulcer is a disease of civilization and more common among the white race than among the dark races. However Peptic ulcer disease is found all over the world. It has been estimated that 5-10% of individuals in the United States suffer from peptic ulcers during their life (Sonnenberg and Everhart, 1996). During 1981 and 1988, the hospitalization rate for peptic ulcer cases throughout the Thailand remained fairly constant at around 0.1% of the total population (Wilairatana *et al.,* 1991). To date, although the cases decline, the diseases are still important because of the death from gastric bleeding in some cases. Moreover, some studies indicated that chronic ulceration or prolonged inflammation may develop gastric cancer (Correa, 1980; Fox and Wang, 2007)

In general, the definition of peptic ulcer is damage in mucosa lining the gastrointestinal tract such as the first part of the duodenum, junction of antral and body mucosa in stomach and distal oesophagus. In most cases, the ulcers are principally found in the duodenum and stomach. The ulcers may be acute or chronic and may be complicated haemorrhage, perforation, obstruction due to fibrous strictures and malignancy. Acute peptic ulcers may develop from a part of acute gastritis, severe stress response or a result of extreme hyperacidity. Chronic peptic ulcers are most likely to occur where acid and pepsin first come into contract with a susceptible mucosa (Johnson,1986, Connors, 2007). For many years, peptic ulceration has been thought to be a consequence of excessive acid production. However, this hypothesis is in controversy. Individuals with gastric ulcers frequently have normal or even subnormal acid production, and over one-half of duodenal ulcer patients do not have hyperacidity. Conversely, many people who are hyper-secretors of acid do not get ulcers. Furthermore, while most ulcers respond initially to anti-acid treatment, they frequently relapse. Discovery of *Helicobacter pylori* by (Marshall and Warren,1982) elucidated that the bacterial infection was the main cause of the ulcers. This led investigators to study the potential role of the bacterial infection in gastritis, peptic ulcer and gastric cancer. Then the concept of management of the ulcer was changed and the ulcers are now accepted as an infectious disease.(Theodore, 2018)

Helicobacter pylori, curved gram negative bacilli, is now recognized as a major cause of

gastritis and peptic ulcer (Marshall and Warren, 1984; Graham, 1999) and is classified as carcinogenic factor for gastric cancer (International agency for research on cancer, 1994). *H. pylorus is* well adapted to colonize in the stomachs of human and other vertebrates for the life span of their hosts. A large number of people around the world are reported to be infected with this organism and also have gastric inflammation. However, most infected individuals do not develop dyspepsia and other gastroduodenal disorder (Kusters *et al.,* 2006; Seid et al., 2018). Therefore, the diagnosis is usually overlooked at the early stage of infection.

The mechanism of *H. pylori* infection that causes peptic ulcer can be described as a multi-step process. Firstly, the organisms have to pass through gastric acid barrier and enter the mucous layer (colonization). Then, they adapt and multiply under the environmental condition of the gastric mucus (persistence). Ultimately, *H. pylori* existing in the gastric mucosa can induce the inflammation and lead to various degrees of gastric tissue destruction.

Ulceration is influence by equilibrium of damaging substances and host mucosal defence. The mucosal defence refers to the process that protects cells or tissues from various substances such as endogenous and exogenous toxins as well as bacterial products that can cause inflammation or ulceration. In general, human may not completely resist to damage induced by these substances, so the mucosal injury happens. However, a repair of this damage can quickly occur in the epithelium. The resistance of the mucosa would be enhanced when toxic substances are present in the lumen of the stomach. The activity of mucosal defence is organized in various processes. The first level of defence consists of the secreted factors in the lumen, including acid, mucus, bicarbonate and antibacterial substances (e.g. Immunoglobulin). The second level of defence is the epithelium which resists to acid-induced injury and acts as a barrier to passive diffusion. Damaged epithelium would be repaired quickly through the processes that involve migration of healthy cells over injury region. The mucosal micro-circulation is the third level of defence that is operated by the nervous system. Diffusion of acid or toxins into the mucosa results in a sensory nerve-mediated elevation of mucosal blood flow that is necessary for limiting the damages and facilitating repairs. The blood dilutes and/or neutralizes the acid/toxin and prevents it from accumulating in the mucosal tissue. The fourth level of defence is the mucosal immune system. This system consists of various cells, such as mast cells and macrophages which respond to the entry of foreign materials into the mucosa and alter an inflammatory response. This level of the defence may produce reactive oxygen species from chronic inflammation. The final level of mucosal defence starts when mucosal damage extends deeper than the superficial epithelium. In this circumstance, the mucosal damage is able to undergo repair that includes growth and re-development of gastric glands, renewed innervations by extrinsic and intrinsic nervous systems and re-establishment of microcirculation through angiogenesis. Nevertheless, the ulcer can develop when the mucosal defence are imbalance to the damaging substances (Malik, 2003).

There are many studies on mucosal defence mechanism against reactive oxygen species in the gastrointestinal tract. The reduced form of the tripeptide thiol, glutathione (GSH) is one of the major endogenous defence mechanisms against oxidative stress. GSH acts as a scavenger of free radicals and toxic substances that produce in the gastrointestinal tract (Lobo *et al*., 2010; Kurutas, 2015; Ighodaro & Akinloye, 2018). GSH protects gastric mucosa cells from damage by nitric oxide and exhibits other beneficial effects as co-substrate for glutathione S-transferase (GSTs) and glutathione peroxidase. Glutathione peroxidase catalyses the degradation of organic or lipid peroxide, whereas GSTs catalyse conjugation of GSH

to a variety of carcinogens and toxins to form less toxic compounds (Reinemer *et al.,* 1991).

Epidemiology of peptic ulcer.

The time trends in the epidemiology of peptic ulcer disease reflect complex, multifactorial etiologies. Peptic ulcer was rare before the 1800s. The pathology of gastric was first described in 1835 (Bratucu *et al.,* 2021). During the late 1800s the prominent form was gastric ulcers in young women. Duodenal ulcers were rare until about 1900 and then became a prevalent condition during the first half of the 20th century. However, in developed countries the mortality from peptic ulcer disease has fallen dramatically for birth cohorts born after the turn of the 20th century (Sonnenberg, 2007).

As noted above, it is now evident that the epidemiology of peptic ulcer disease largely reflects environmental factors. The influence of environmental factors on the pattern of gastritis may be a key variable in these birth-cohort's effects. At the end of the 19th century (and currently in many developing countries) H. pylori infection was characterized by pangastritis involving the gastric antrum and body and leading to acid hypo-secretion, which predisposed to gastric cancer and gastric ulcer (Graham *et al.*, 2003). In contrast, duodenal ulcers are associated with antral-predominant gastritis that spares the acid-secreting body, but is negatively associated with more or severe body gastritis and with gastric cancer (Calam and Baron, 2001; Graham *et al.*, 2003). The reason is that duodenal ulcers require acid secretion to be preserved, which cannot be achieved in the face of moderate body gastritis, whereas gastric cancer is associated with hypo-chlorhydria.

Chemical Constituents

Many scientific analyses have shown that soursop contains many nutrients, including, protein, sugar, fatty acids, dietary fibre, vitamin C, B1, B2, iron, magnesium, manganese, potassium chloride. It also contains many bioactive compounds and phytochemical, such as alkaloid, citric acid, malic acid, stearic acid, stepharine, tannin, vinblastine etc. (Kossouh *et al.,* 2007)

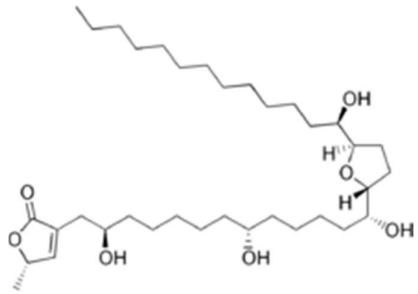

Annonacin.

The compound annonacin, which is contained in the seeds of sour sop, is a neurotoxin associated with neurodegenerative disease. (Abubacker and Deepalakshmi, 2013)

The leaves of *Annona muricata* contain annonamine, which is an aporphine-class alkaloid featuring a quaternary ammonium group. (Matsushige *et al.,* 2012)

Components of Sour Sop (raw)

Nutritional Value per 100g (3.5oz)	
Energy	66kcal
Carbohydrates	16.84g
Sugars	13.54g
Dietary fibre	3.3g
Fat	0.3g
Protein	1g

Vitamins		
Thiamine (B_1)	0.07mg	6%
Riboflavin (B_2)	0.05mg	4%
Niacin (B_3)	0.9mg	6%
Pantothenic acid (B_5)	0.253mg	5%
Vitamin B_6	0.059mg	5%
Folate (B_9)	14 µg	4%
Choline	7.6mg	2%
Vitamin C	20.6mg	25%
Minerals		
Calcium	14mg	1%
Iron	0.6mg	5%
Magnesium	21mg	6%
Phosphorus	27mg	4%
Potassium	278mg	6%
Sodium	14mg	1%

(Wikipedia2017)

Caution.

(i) Sour sop has been found to be a potent uterine stimulant. Therefore, it should be avoided during pregnancy.

(ii) High doses of infusion or decoction may cause nausea and vomiting.

(iii) Those taking prescription antihypertensive and antidepressant drugs are advised to be careful with soursop, because it may potentiate these drugs.(guardian.ng, 2017)

Other Herbs for treating gastric ulcers include;

Ginseng

Panax ginseng root may have antimicrobial properties; it is a traditional remedy for infections. Researches at Ajou university school of medicine in Korea, tested another variety, red *ginseng,* against infected gastric cells with DNA damage caused by *H. Pylori.* S. park and colleagues observed that red *ginseng* extract inhibited the growth of *H.* pylori and protected against cell damage. (Pubmed.gov, 2017)

Result of study published in July 2005 “Digestive Diseases and Sciences” suggests the herb could be a natural medicine to treat peptic ulcers caused by infection. Broccoli sprout, garlic and cranberry are other plants

reputed to fight *H. pylori* bacteria (Pubmed.gov, 2017).

DGL Licorice

Ordinary licorice contains glycyrrhizinic acid, a substance responsible for the herb's side effects of blood pressure elevation and numerous drug interactions. "Deglycyrrhizinated", or DGL, licorice is a form thought to be safe for long-term use, as the harmful ingredient has been removed. The university of Maryland Medical Centre reports that DGL licorice may protect against stomach damage from nonsteroidal anti-inflammatory medications such as aspirin and ibuprofen. Licorice may be combined with other herbs such as bupleurum and angelica, to treat ulcers Also, teas made from marshmallow root, slippery elm bark or flax seeds may soothe irritated gastric mucosa (Nihar *et al.,* 2017)

Methodology.

Materials/Apparatus.

Plastic cage, Feeding containers, Crude methanolic extract of *Annona muricata,* Gloves, Cotton wool, Sensitive and digital weighing balance, Water bath, Methanol, Syringes, Normal saline, Oesophago-gastric cannula, Neutral buffered formalin, Chloroform, Pellet, Reagent bottles, Specimen bottles, Measuring cylinder, Light microscope fitted with 5mp camera, Dissecting set, Glass slide, Cover slip, Beakers, Petri dish, Blender, Filter paper, Aluminium foil paper.

Animals

Twenty-one (21) presumptively healthy rats of both sexes between the weight range of 100 g and 150 g from Bowen University farm house and kept in plastic cages. The rats were fed pellet and water ad libitum.

Duration of Experiment

The experiment lasted for approximately 3 weeks, 2 weeks for acclimatisation, 1 day for inducing ulcer and 1 week for treatment with methanolic extract of *Annona muricata.*

Preparation of the *Annona muricata* Leaves Extract

The sour sop leaves were plucked from a sour sop tree and dispersed widely on the ground, in order to dry at room temperature for about 4 days. After the leaves were appropriately dried, it was grounded into powdery form, which had a net weight of about 0.84 kg. The quantity of the methanol used for the extraction was approximately 7 litres. Extraction preceded involving the following processes; soaking, filtration and evaporation.

Soaking.

Seven (**7**) litres of methanol were mixed thoroughly with the dried grounded sour sop leaves and left in seven 1000 ml glass beakers covered with aluminium foil and rubber bands for 96 hours.

Filtration.

The solution was filtered using filter paper, measuring cylinder as well as cloth strainer.

Evaporation.

This process was carried out by the use of rotary evaporator; the concentrated extract was obtained and had a net weight of 36.273 kg, which was then kept at room temperature.

Dilution of the Extract.

The extract was diluted with distilled water before administration, in relation to the weight of the rats.

Figure 3.4.1: Soursop leaves in the process of drying (at room temperature).

Experimental Design.

The 21 wistar rats were grouped into three, having 7 rats in a group. The experiment was organized as follows;

GROUP 1: The animals were given normal saline first thing in the morning. This was the control group.

GROUP 2: The animals were orally given absolute ethanol (5 mL/kg), after 24 hours fasting, to induce ulcer. They were sacrificed an hour later and their stomach harvested and preserved for histological assessment.

GROUP 3: The animals were orally given the methanolic extract of soursop leaves, which was used to treat the gastric injury (ulcer). They were treated for one week.

The extracts were administered using oral cannula (Oesophago-gastric tube)

Tissue Preparation.

The experimental animals were sedated using chloroform. They were sacrificed, their stomachs harvested and the content was carefully removed and the stomach was rinsed.

For staining, the routine Hematoxylin and Eosin (H&E), Periodic acid Schiff (PAS), and Van Gieson were used with diastase to stain the stomach tissue.

Macroscopic Analysis of Gross Appearance of the Stomach

The rodents that were administrated with absolute ethanol experienced severe damage compared to the normal control group, which was evidenced by development of haemorrhagic ulceration. The consequent haemorrhagic detriment was conspicuously attenuated by treatment with methanolic extract of *Annona muricata* at 200 mg/kg dose with a few hyperaemia, compared to the normal control group.

Figure 3.4.2: Dried and Grounded soursop leaves.

Figure 3.4.3: The soaked soursop leaves in methanol to obtain extract

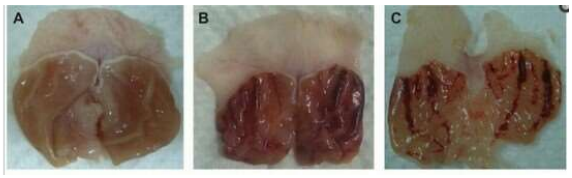

Figure 4.1.1: Images of the stomach of groups A, B and C.
A: Normal control group.
B: Lesion control group
C: Group treated with 200 mg/kg of methanolic extract of *Annona muricata.*

Microsopic Analysis

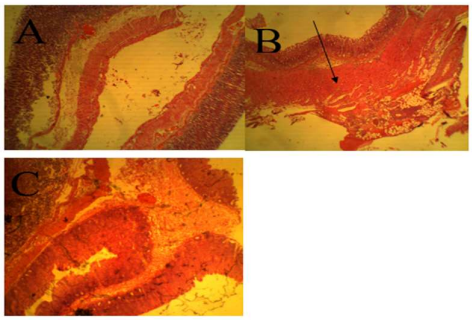

PLATE 1:
Histopathological staining of gastric tissues of control group (A), Ulcer-induced group (B) and the group treated with Annona muricata at 200 mg/kg (C). H&E staining(X4).
Observe the prominent presence of the four distinct layers: Mucosa, submucosa, muscular layer and serosa respectively in the control group.
In the ulcer-induced group, there are clear signs of haemorrhage (black arrow) majorly at the submucosal level compared to the control group and in group C, the presence of haemorrhage is not as prominent as observed in lesion group (B).

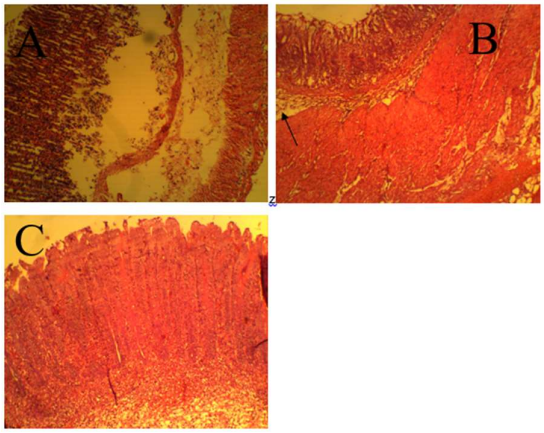

PLATE 2:
Histopathological staining of gastric tissues of group A, B and C. H&E staining at X10.
In the lesion group (B), there are signs of leukocyte infiltration (black arrow), where as in group C there is attenuation of leukocyte infiltration. Also, there is damage at the epithelium level.

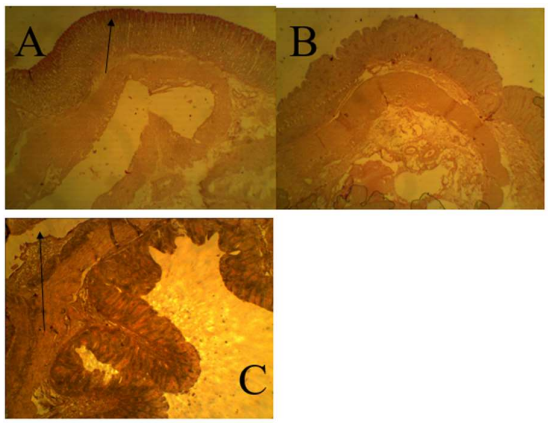

PLATE 3:
showing gastric tissues of each group using PAS staining at X4. PAS staining illustrated accumulation of glycogen (magenta coloured regions) in the control group and slightly in the treated group(C). There is complete absence of glycogen in the lesion group (B).

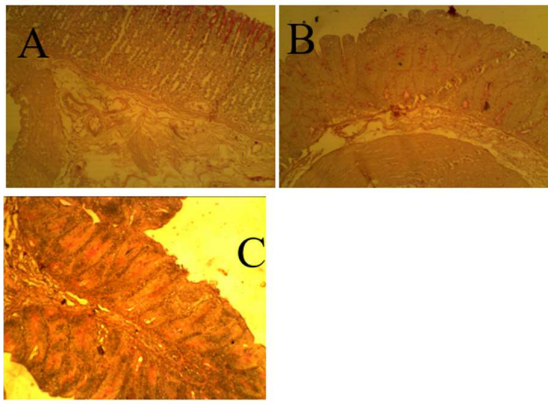

PLATE 4:
showing gastric tissues of each group using PAS staining at X10. In control group gastric pits are evident and are somewhat visible in treated group(C). However, they are diminished in the lesion group.

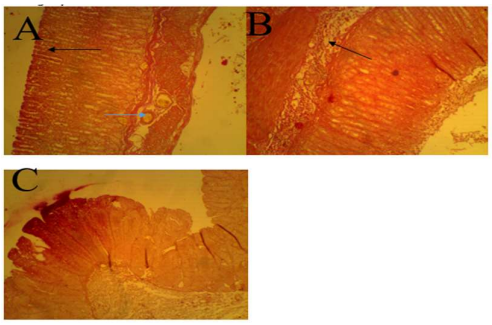

PLATE 5:
Showing gastric tissues of each group using Van Gieson staining at X10.
Observe in group A, the significant presence of collagen fibres (black arrow) and blood vessels (blue arrow). In group B presence of collagen fibres and elastic fibres intertwined. However, there is a reduction in both collagen and elastic fibres in group C.

Morphometric Results.

Histo-morphometric analysis of stomach of group A animals showed no mucosal damage, groups B and C showed reasonable levels of damage that are statistically represented on the table below with measurements done in micrometres.

TABLE 4.3.1: MEAN THICKNESS OF GASTRIC MUCOSA (±)

GROUPS	VALUES
GROUP A	30788.8
GROUP B	18793.5
GROUP C	23785.1

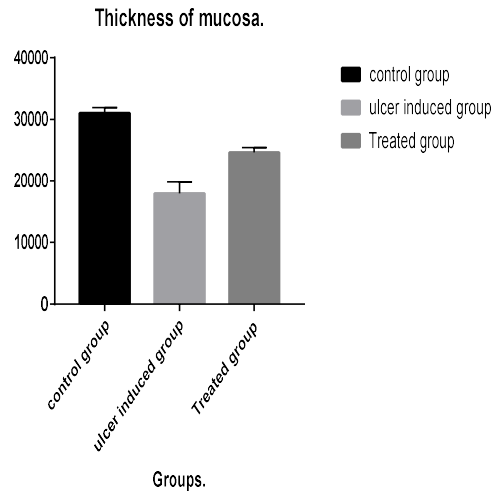

p>0.05 showing statistical significance

Discussion, Conclusion and Recommendation.

Discussion.

In the histopathological study of gastric ulcer, various characteristics are considered to determine the stage of histological change such as haemorrhage, leukocyte infiltration, glycogen content and thickness of the mucosa. Nutraceuticals, including dietary supplements, functional foods and herbal products have maintained their importance in treatment of various ailments and diseases, irrespective of the extensive development of synthetic drugs in the pharmaceutical industry (Moghadamtousi *et al*., 2014). In recent years, considering the prominence of gastric injury and unpredictable side effects of long-term use of synthetic drugs, interest in the use of herbal products has markedly elevated (Falcao *et al.,* 2008). In this study, we examined the antiulcer effects of methanolic extract of *Annona muricata* against ethanol-induced gastric injury in rats similar to work done by Moghadamtousi *et al.,* 2014

Histological comparison of the stomach across the various groups for H& E, PAS and VVG at X4 magnification showed considerable difference in morphology, in that, the thickness of the mucosa for the control group was greatest, whereas that of the ulcer-induced group's mucosa was significantly diminished and the group treated with methanolic extract of *Annona muricata* had their mucosa improved but not as the control group. Also, I observed presence of glycogen in the epithelia layer of the control group, the presence of glycogen was noted by its magenta colouration. However, it was completely absent in ulcer-induced group and signs of presence in treated group.

Another observation worthy of note is the presence of damaged mucosa and

submucosa, also haemorrhage in the ulcer-induced group, however, this was somewhat regenerated in the group treated with methanolic extract of *Annona muricata.* Leukocyte infiltration was noted in the ulcer-induced group.

For the group, treated with *Annona muricata* loss of weight and appetite was observed for the first 2-3 days, however, this improved subsequently.

In general, the restorative effect of Annona muricata on gastric ulcer is highly significant.

The results obtained from this study can be compared with past work by Moghadamtousi *et el.*, 2014, who worked on "The gastro-protective activity of *Annona muricata* leaves against ethanol-induced gastric injury in rats" and the result deduced was Oral administration of ethyl extract of *Annona muricata* (200 mg/kg and 400 mg/kg) markedly protected the gastric tissue from haemorrhagic lesions associated with attenuation of leukocyte infiltration and submucosal edema.

Conclusion and Recommendation.

The results obtained in this study showed the safety of methanolic extract of *Annona muricata.* However, further chronic toxicity testing should be conducted to confirm its safe usage. In vivo study in rats demonstrated the promising antiulcer effect of methanolic extract of *Annona muricata* against gastric mucosal injury induced by ethanol. Methanolic extract of *Annona muricata* mediated its antiulcer potential probably by protective effect against gastric wall mucus damage. An investigation on the major active compound in methanolic extract of *Annona muricata* is still required, to fully illustrate the antiulcer potential of the leaves.

Reference

Abubacker, M.N. and Deepalakshmi, T (2013). *In vitro* Antifungal Potentials of Bioactive Compound Methyl Ester of Hexadecanoic Acid Isolated from *Annona muricata* Linn. (Annonaceae) Leaves *BIOSCIENCES BIOTECHNOLOGY RESEARCH ASIA*. Vol. **10**(2), 879-884 DOI: http://dx.doi.org/10.13005/bbra/1211

Brătucu MN, Prunoiu VM, Strâmbu V, Brătucu E, Răvaş MM, Simion L, Petre R.(2021). Unusual Complicated Gastric Ulcers. Medicina (Kaunas).9;57(12):1345. doi: 10.3390/medicina57121345. PMID: 34946290; PMCID: PMC8703598.

Brzozowski T, Konturek PC and Konturek SJ, (2000) "Role of gastric acid secretion in progression of gastric erosions induced by ischeamia-reperfusion into gastric ulcers". *Eur J Pharmacol*; 398(1):147-158.

Calam J, Baron J.H. (2001). ABC of the upper gastrointestinal tract: Pathophysiology of duodenal and gastric ulcer and gastric cancer. BMJ. 27;323(7319):980-2. doi: 10.1136/bmj.323.7319.980. PMID: 11679389; PMCID: PMC1121510.

Connors, John M Ulcers, (2007). Editor(s): S.J. Enna, David B. Bylund, xPharm: The Comprehensive Pharmacology Reference, Elsevier, Pages 1-8,

ISBN 9780080552323, https://doi.org/10.1016/B978-008055232-3.60706-8.

Correa P. (1980). The epidemiology and pathogenesis of chronic gastritis: three etiologic entities. *Front. Gastrointest. Res.*;**6**:98–108.

Drini M. (2017). Peptic ulcer disease and non-steroidal anti-inflammatory drugs. Aust Prescr. 2017 Jun;40(3):91-93. doi: 10.18773/austprescr.037. Epub 2017 Jun 1. PMID: 28798512; PMCID: PMC5478398.

Falcao HS, Mariath IR, Diniz MF, Batista LM, and Barbosa-Filho JM, (2008). "Plants of the American contient with anti-ulcer activity"; 15 (1-2): 132-146.

Fox JG, Wang T.C. (2007).Inflammation, atrophy, and gastric cancer. J Clin Invest. 117(1):60-9. doi: 10.1172/JCI30111. PMID: 17200707; PMCID: PMC1716216.

Graham D.Y.(1999). *Helicobacter pylori*, GERD, NSAIDs, and cancer: where we really stand. *Am J Gastroenterol.* ;**94**:1420–1421. doi: 10.1111/j.1572-0241.1999.01420.

Graham, David Y.. Changing patterns of peptic ulcer, gastrooesophageal reflux disease and Helicobacter pylori:: a unifying hypothesis. European Journal ofGastroenterology & Hepatology 15(5):p 571-572.DOI: 10.1097/01.meg.0000059103.41030.d2

Holdsworth D. K. (1990): "Traditional Medicinal Plants of Rarotonga, Cook Islands." Part I. Int. J. Crude Drug Res. 28(3), 209-218.

Ighodaro .M. & Akinloye O.A. (2018) First line defence antioxidants-superoxide dismutase (SOD), catalase (CAT) and glutathione peroxidase (GPX): Their fundamental role in the entire antioxidant defence grid, Alexandria Journal of Medicine, 54:4, 287-293, DOI: 10.1016/j.ajme.2017.09.001

Johnson, L.R. (1986). Pathophysiology of Peptic Ulcer Disease. In: Andreoli, T.E., Hoffman, J.F., Fanestil, D.D., Schultz, S.G. (eds) Physiology of Membrane Disorders. Springer, Boston, MA. https://doi.org/10.1007/978-1-4613-2097-5_47

Kossouoh C, Moudachirou M, Adjakidje V, Chalchat JC, Figuérédo G. (2007). Essential oil chemical composition of Annona muricata L. leaves from Benin. J Essent Oil Res. ;19(4):307-9

Kurutas, E.B. (2015). The importance of antioxidants which play the role in cellular response against oxidative/nitrosative stress: current state. *Nutr J* **15**, 71 https://doi.org/10.1186/s12937-016-0186-5

Kusters JG, van Vliet A.H, Kuipers E.J.(2006). Pathogenesis of Helicobacter pylori infection. Clin Microbiol Rev.;19(3):449-90. doi: 10.1128/CMR.00054-05. PMID: 16847081; PMCID: PMC1539101.

Lobo V, Patil A, Phatak A, Chandra N. (2010). Free radicals, antioxidants and functional foods: Impact on human health. Pharmacogn Rev.;4(8):118-26. doi: 10.4103/0973-7847.70902. PMID: 22228951; PMCID: PMC3249911.

Malik TF, Gnanapandithan K, Singh K. (2023). Peptic Ulcer Disease. In: StatPearls [Internet]. Treasure Island (FL): StatPearls Publishing; 2023 Jan-. Available from: https://www.ncbi.nlm.nih.gov/books/NBK534792/

Marshall B.J, Warren R.M. (1984). Unidentified curved bacilli in the stomach of patients with gastritis and peptic ulceration. *Lancet.*;**16**:1311–1315. doi: 10.1016/S0140-6736(84)91816-6

Matsushige A, Kotake Y, Matsunami K, Otsuka H, Ohta S, Takeda Y. (2012). Annonamine, a new aporphine alkaloid from the leaves of Annona muricata. Chem Pharm Bull (Tokyo).;60(2):257-9. DOI: 10.1248/cpb.60.257, PMID 22293487.

Moghadamtousi, Soheil Zorofchian; Karimian, Hamed; Rouhollahi, Elham; Paydar, Mohammadjavad; Fadaeinasab, Mehran and Abdul Kadir, Habsah, (2014). Annona muricata leaves induce G1 cell cycle arrest and apoptosis through mitochondria-mediated pathway in human HCT-116 and HT-29 colon cancer cells, *Journal of Ethnopharmacology,*Volume 156,Pages 277-289, ISSN 0378-8741, https://doi.org/10.1016/j.jep.2014.08.011.

Morton, JF (1987); Soursop In: Fruits of warm climates. Miami, Florida: p.75-80.

Reinemer, Peter; Dirr, Heini W, Ladenstein1,Rudolf Schaffer,Jorg Gallay, Oliver and Huber, Robert, (2005). The three-dimensional structure of class wr glutathione S-transferase in complex with glutathione sulfonate at 2.3 A resolution The EMBO Journal vol.10 no.8 pp.1997-2005.

Nihar, Kar Ranjan; Shreechandan, Paikaray; Priyadarshini, Parida and Sampad, Swain Sabhya (2017). Herbal Drugs in Treatment of Peptic Ulcer *J.Bio.Innov6 (3),* pp: 499-508, |ISSN 2277-8330 *(Electronic)*

Seid A, Tamir Z, Demsiss W. (2018). Uninvestigated dyspepsia and associated factors of patients with gastrointestinal disorders in Dessie Referral Hospital, Northeast Ethiopia. BMC Gastroenterol. 18;18(1):13. doi: 10.1186/s12876-017-0723-5. PMID: 29347978; PMCID: PMC5774098.

Sonnenberg A, Everhart J.E.(1996). The prevalence of self-reported peptic ulcer in the United States. Am J Public Health.;86(2):200-5. doi: 10.2105/ajph.86.2.200. PMID: 8633736; PMCID: PMC1380328.

Sonnenberg A. (2007). Time trends of ulcer mortality in Europe. Gastroenterology.;132(7):2320-7. doi: 10.1053/j.gastro.2007.03.108. Epub 2007 Apr 14. PMID: 17570207.

Theodore H. Tulchinsky, Warren, Marshall, (2018). Helicobacter Pylori, Peptic Ulcers and Gastric Cancer, Editor(s): Theodore H. Tulchinsky, Case Studies in Public Health, Academic Press, Pages 543-560, ISBN 9780128045718,

https://doi.org/10.1016/B978-0-12-804571-8.00006-8.

Thorsen K, Soreide JA, Kvaloy JT, Glomsaker T and Soreide K, (2013). "Epidemiology of perforated peptic ulcer: age- and gender- adjusted analysis of incidence and mortality" ;19(3): 347-354.

Wilairatana S, Kladchareon N, Israsena S, Wilairatana P. (1991). Epidemiology of peptic ulcer disease in Thailand. Gastroenterol Jpn. ;26 Suppl 3:265-6. doi: 10.1007/BF02779317. PMID: 1884952.